

Diabetic Neovascularization Identification from Fundus Images Retinopathy

Sandeep K^{1}, Raju B², Chandra Reddy M³, Vamshi Krishna M⁴, Rohan D⁵*

and *Abhilash M⁶*

¹Assistant Professor, Department of Information Technology, GRIET, India

^{2,3,4,5,6}Student, Department of Information Technology, GRIET, India

Abstract. Proliferative Diabetic Retinopathy (PDR) is a retinal disease that can affect people with diabetes and cause visual loss if left untreated. Detecting neovascularization, an abnormal growth of veins in the retina, can be difficult due to its irregular pattern and small size. To improve detection, deep learning algorithms, such as MobileNet, are being used to automate complex object recognition. In a neovascularization affirmation technique based on transfer learning, multiple pre-trained models were built during the training phase, including MobileNet, CNN with SVM, AlexNet, GoogleNet, ResNet, ResNet18, and ResNet and GoogleNet models. Machine learning models for HOG feature extraction were also implemented, such as Random Forest, Decision Tree, Gradient Boosting, Support Vector Classifier, and Voting Classifier. MobileNet performed the best and was used to build the model for predicting results from user-uploaded images.

1 Introduction

People with long-term diabetes are more likely to develop diabetic retinopathy (DR), which has two types: NPDR and PDR. NPDR symptoms include cotton wool patches, hard exudates, microaneurysms, and hemorrhages. PDR is a more severe form that carries a high risk of visual impairment due to the growth of small, unpredictable veins called neovascularization in the retina. Lack of oxygen supply in vessels is a primary cause of this problem, leading to retinal discharge and vision problems. Neovascularization at the optic disc (NVD) and elsewhere (NVE) can cause vision problems due to the formation of vessels and glassy bleeding. It's important to see an ophthalmologist whenever neovascularization is present. Early recognition of PDR is crucial to preserve the patient's vision. Fundus imaging can identify neovascularization, which is still difficult to recognize despite various techniques for blood flow analysis. The retinal vasculature provides important information about the body's microcirculation without the need for drugs. Improved computer diagnostic algorithms can enhance neovascularization detection accuracy during subsequent visits or telemedicine consultations. More reliable detection would lead to patients being less likely to miss out on optimal and effective laser treatment. Neovascularization presents extra

* Corresponding author: sandeepreddy283@gmail.com

challenges due to its varying structure and size, highlighting the need to develop an automated identification system.

2 Literature Survey

Epidemiological issues in diabetic retinopathy [1] Due to changing lifestyles, obesity, and an aging population, the world is currently experiencing a diabetes pandemic, mostly type 2 diabetes. By 2030, the number of diabetics worldwide will rise to 552 million, according to the International Diabetes Federation (IDF). Finland has the most elevated paces of type 1 diabetes in the Northern Half of the globe, and there is proof of an expansion in specific focal European nations, especially among more youthful kids younger than five. Numerous modifiable risk factors, such as smoking, serum lipids, and pulse, influence the progression of diabetic retinopathy (DR). Age, gender, height, and genetic predisposition are examples of non-modifiable risk factors. Pregnancy, the number of microaneurysms in one eye, the rate at which they are arranged, and any DR in the other eye are all risk factors. The earlier risk factors did not completely set the rates of diabetes related macular edema (ME) or proliferative diabetic retinopathy (PDR). In one study on type 1 diabetes, the median age at which a person is most likely to develop early retinal irregularities was 9.1. Proliferative retinopathy had a 25-year occurrence of 42.9% in a population partner of type 1 diabetes patients, as per another review. Further developed administration of glucose, circulatory strain, and serum lipids, as well as prior conclusion, may have decreased the pace of movement to PDR and extreme vision misfortune in diabetics lately.

Prevalence and the associated burden of illness of symptoms of diabetic peripheral neuropathy and diabetic retinopathy [2] We decided the predominance and illness weight of diabetic peripheral neuropathy (SDPN) and diabetic retinopathy (DR) among grown-ups with diabetes in the US who were more than 40 years of age, and we consolidated SDPN and DR. moving fully expecting a get-together. Looking at loads were used to evaluate the number of diabetic patients with SDPN, DR, or both. To explore how SDPN, DR, and comorbid SDPN and DR impacted issue ailment markers, 9 multivariate backslide models were utilized. Diabetes influences roughly 11.9 million individuals north of 40 in the US. There are 3.9 million individuals with SDPN (32.7%), 3.3 million with DR (26.4%), and 1.6 million with both. The odds ratios (ORs) for SDPN casualties are 2.25; DR (OR=1.68; OR=2.84; 95% certainty stretch (CI)=1.32-3.83; SDPN and DR in mix (95% CI=1.26-6.41), or SDPN and DR alone (95% CI=1.08-2.61)) were more probable than those without a similar condition to have made no less than four visits to the expert in the earlier year. SDPN in adults between the ages of 40 and 65 (OR=3.23) OR=2.94; DR OR=4.32; 95 percent CI=1.60-6.52). SDPN and DR (95 percent CI = 2.18 to 7.63) were bound to be jobless. In the United States, diabetics over the age of 40 have normal SDPN, DR, and comorbidity SDPN and DR; Each of these issues has the potential to substantially increase the burden of disease.

Association between diabetic eye disease and other complications of diabetes Implications for care. A systematic review [3] To investigate the potential implications of the associations between common diabetes mellitus micro- and macrovascular problems and diabetic retinopathy (DR). Materials and Strategies A thorough hunt of the PubMed informational index uncovered examinations including diabetics researching the beginning or movement of DR according to other diabetic vascular circumstances. Results We found that DR is much of the time related with other diabetic issues, and that the seriousness of DR is connected to an expanded gamble of the event or improvement of extra miniature and macrovascular issues. Specifically, DR raises the gamble of nephropathy and is serious areas of strength for an of stroke and cardiovascular illness. As DR advances, this chance ascents emphatically. A significant gamble factor for fringe vascular sickness, which can bring about lower appendage ulcers and removal, is proliferative diabetes. What's more, our information

demonstrate that DR patients have a more regrettable visualization than non-DR patients. The review's decision underlines the need of a planned and cooperative way to deal with patient consideration. The presence and seriousness of DR can be utilized to distinguish patients at expanded risk for miniature and macrovascular intricacies, taking into consideration prior identification, reference, and intercession fully intent on lessening diabetic horribleness and mortality. This is conceivable on the grounds that DR screening programs that can be done beyond an ophthalmology office are broadly utilized and by and large practical. Experts in diabetes care should always encourage DR screenings.

Early detection of proliferative diabetic retinopathy in neovascularization at the disc by observing retinal vascular structure [4] A serious type of diabetic retinopathy (DR) with a high gamble of vision misfortune is Proliferative Diabetic Retinopathy, or PDR for short. During this stage, strange vessels multiply, resulting in neovascularization. A semi-computerized technique for distinguishing PDR in retinal pictures around a couple of Optic Disc (OD) widths is introduced in this work. Even though the technique focuses on neovascularization at the disc (NVD), it is essential to identify the OD focal point from sectioned images. Around the OD community, the estimated width of the principal vessels is estimated and numbered on a window line a few pixels apart. In the end, unmistakable tones recognize the fundamental vessels. The responsiveness and particularity results for the 25-photograph Gaze dataset are 0.86 and 0.87, individually. The technique has a precision of 0.88 overall.

A new supervised retinal vessel segmentation method based on robust hybrid features [5] In this review, we present an original strategy for managed retinal vein division that joins a mixture highlight vector for pixel characterization with an assortment of very tough qualities from various methodologies. The B-COSFIRE channel reaction, contrast improved force, morphological formal hat changed power, vesselness measure, and 13 Gabor channel reactions that have been determined in various arrangements make up this 17-D component vector. An irregular timberland classifier that is famous for its speed, effortlessness, and data combination capacity is prepared utilizing the half and half element vector. The chose mix of numerous autonomously solid highlights 11 brings about more noteworthy nearby data and predominant separation for vessel and non-vessel pixels in retinal pictures of sound and ailing retinas. Two openly accessible datasets, DRIVE and Gaze, are utilized to test the proposed procedure completely. In the DRIVE and Look datasets, typical request correctness of 0.9513 and 0.9605 are achieved, independently. Our technique performs better compared to current strategies when most normal execution measurements are considered. Execution information show that, in broadly educating and obsessive situations, our procedure beats current methods

3 System Architecture

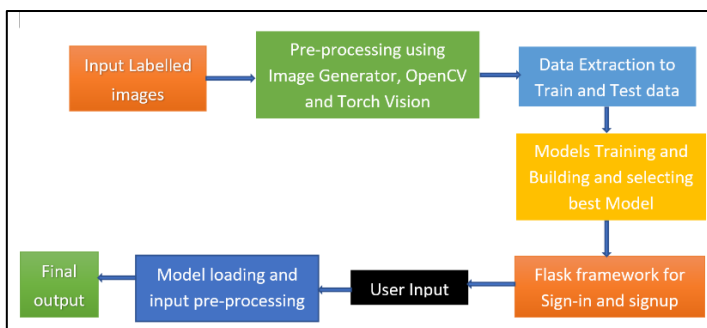


Fig. 1. System Architecture.

4 Methodology

Various investigations have shown that image processing calculations can consequently recognize cotton fleece patches, hard exudates, hemorrhages, and microaneurysms. Be that as it may, because of challenges in recognizing ordinary veins and recently shaped veins, neovascularization distinguishing proof examination is still in its beginning phases. Likewise, there aren't numerous photographs of named neovascularization, which is keeping down progress in the field. Approaches in light of angiography might offer a total image of the retina. Nonetheless, because of their obtrusive nature, these methods are normally not suggested, especially for standard or beginning phase diagnostics.

Disadvantages:

1. Neovascularization location is still in its early stages because of the trouble of recognizing standard veins from recently framed veins.

In order to distinguish neovascularization, this study applied deep learning techniques based on transfer learning. Along with certain machine learning models like Random Forest, Decision Tree, Gradient Boosting, and others, the pre-trained networks include MobileNet, ResNet18, ResNet, AlexNet, and GoogleNet. Additionally, we were in charge of evaluating the effectiveness of the approach for neovascularization differentiation as well as the transfer learning outcomes. We demonstrated that when it came to identifying neovascularization, the suggested network MobileNet outperformed well while comparing to other pre-trained networks.

Advantages:

1. Enhanced performance
2. High levels of specificity, accuracy, sensitivity, and precision may be attained by the proposed network.

4.1 Dataset

The MobileNet which is a pre-trained model used for image classification. Dataset include various fundus images which are classified into five classes like Mild, Moderate, No_DR, proliferative_DR and Severe_DR. The Dataset is taken from the <https://we.tl/t-dtPWffp7pO>

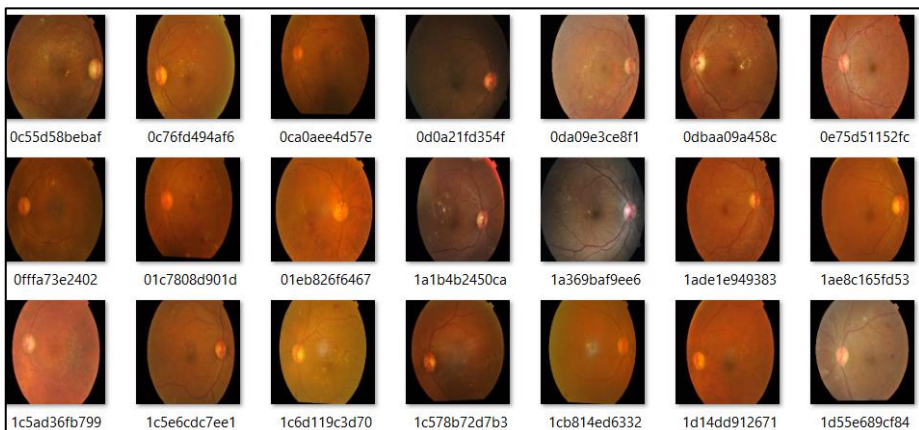


Fig. 2. Input Images.

4.2 Modules and Workflow

1. Importing all the libraries.
2. Exploring the dataset.
3. Image processing using Image Data Generator and the operations include Re-scaling the image, Shear Transformation, Zooming the Image, Horizontal Flip, Reshaping the Image.
4. Using Python libraries like OpenCV and pillow and torch vision operations like Resizing the image, Creating the square background image, Transforming the image using tensor, Reading the image, and computing HOG features.
5. Data extraction to train and test data.
6. Model building during this phase pre-trained models for image processing like MobileNet, ResNet18, AlexNet, GoogleNet, CNN with SVM have been generated and for HOG feature extraction machine learning models like Random Forest, Gradient Boosting, Decision Tree, and Voting Classifier have been generated.
7. Training the models with train and test data and selecting the best model that gives greater accuracy.
8. FLASK Framework with SQLITE for signup and sign-in.
9. User gives the input and input being processed like reshaping the image and converting the image into the array using the keras.
10. Trained model is used for Prediction.
11. Final outcome is displayed.

4.3 Algorithm

MobileNet: MobileNet is a type of pre-trained model for computer algorithms called convolutional neural networks (CNNs) that are made specifically for mobile and small devices that have limited computing power. The goal of MobileNet is to make these algorithms less complicated and use less memory than traditional ones while still being accurate.

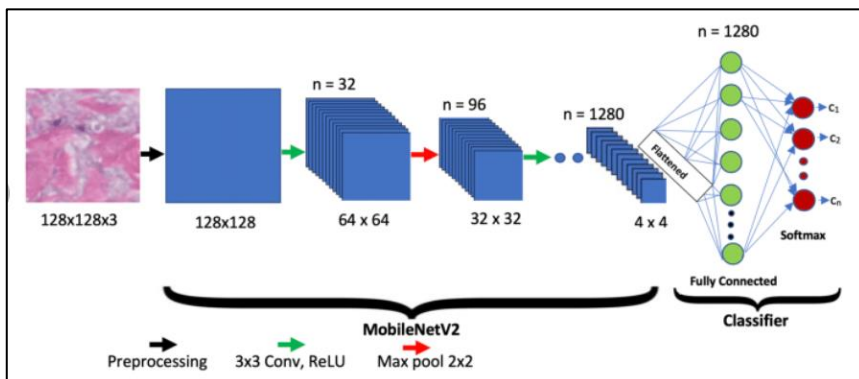


Figure.3. Workflow of MobileNet

The internal working of MobileNet on a given image typically involves the following steps:

1. Image Processing

2. Convolution layers
3. Depth-wise Separable Convolution
4. Activation Functions
5. Pooling
6. Fully Connected Layers
7. Soft max
8. Predicting and Post-Processing

5 Results Analysis

5.1 Input:

The input for the model is a fundus image which is classified into five different classes like Mild, Moderate, No-DR (Diabetic Retinopathy), Proliferative-DR, Severe-DR. We can choose any image from the above cited classes.

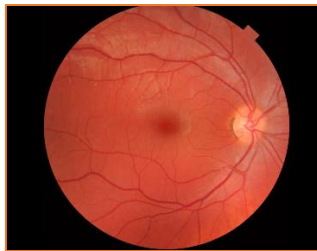

Fig. 4. Input Image

5.2 Output:

The Output for the model is the prediction from the given five classes.

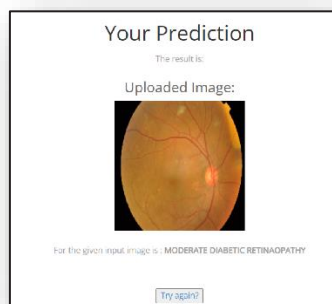


Fig.5. Model Output1 Mild DR

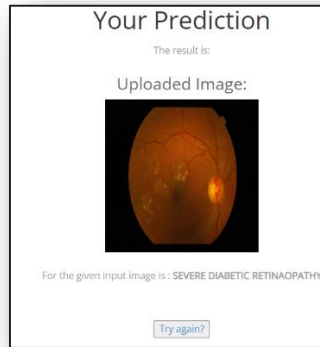


Figure.6. Model output2 Severe-DR

5.3 Analysis:

Results of this study demonstrate that various pre-trained models, such as MobileNet, ResNet, ResNet 18, AlexNet, GoogleNet, and ResNet + GoogleNet, have been developed for image processing, and machine learning models, such as Random Forest, Decision Tree, Gradient Boosting, and Voting Classifier, have been developed for the extraction of HOG features. The following tables provide information about performance of the models described above.

5.3.1 Tables:

TRANSFER LEARNING	ACCURACY
1.MobileNet	0.9765
2.ResNet + Google Net	0.7567
3.CNN with SVM	0.7228
4.ResNet	0.7168
5.AlexNet	0.7108
6.ResNet18	0.7043
7.GoogleNet	0.6895

Figure.7. Pre-trained Models

MACHINE LEARNING	ACCURACY
1. Random Forest	0.75
2. Support Vector Classifier	0.72
3. Voting Classifier	0.71
4. Decision Tree	0.68
5. Gradient Boosting	0.67

Figure.8. Machine Learning Models

5.3.2 Graphs

1) Mobile Net

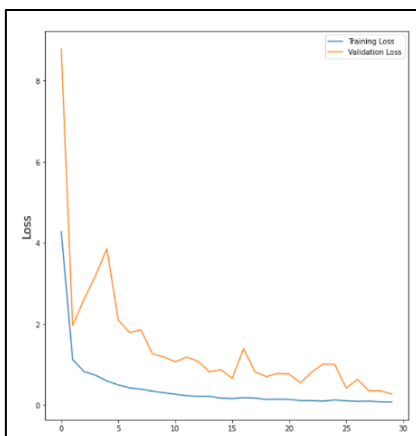


Figure.9. Training and validation loss of MobileNet

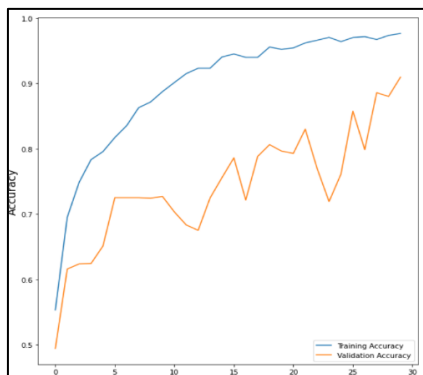


Figure.10. Training and validation accuracy of MobileNet

6. Conclusion

In this project, a transfer learning strategy was presented that takes neo-vascularization into consideration. For image processing, we used pre-trained models like MobileNet, CNN with SVM, AlexNet, GoogleNet, ResNet, ResNet 18, and ResNet + GoogleNet. We also used machine learning models like MobileNet, CNN with SVM, AlexNet, GoogleNet, ResNet, ResNet + GoogleNet, and finally, we noticed that Mobilenet produced the highest accuracy among all the models, so we decided to use MobileNet in our research. Using the flask framework, we created the user's front end.

References

1. P. Scanlon, S. Aldington, and I. Stratton, "Epidemiological issues in diabetic retinopathy," *Middle East Afr. J. Ophthalmol.*, vol. 20, no. 4, p. 293, 2013, doi: 10.4103/0974-9233.120007
2. S. D. Candrilli, K. L. Davis, H. J. Kan, M. A. Lucero, and M. D. Rousculp, "Prevalence and the associated burden of illness of symptoms of diabetic peripheral neuropathy and diabetic retinopathy," *J. Diabetes Complications*, vol. 21, no. 5, pp. 306–314, Sep. 2007, doi: 10.1016/j.jdiacomp.2006.08.002.
3. I. Pearce, R. Simó, M. Lövestam-Adrian, D. T. Wong, and M. Evans, "Association between diabetic eye disease and other complications of diabetes: Implications for care. A systematic review," *Diabetes, Obesity Metabolism*, vol. 21, no. 3, pp. 467–478, Mar. 2019, doi: 10.1111/dom.13550.
4. S. Loukovaara, E. Gucciardo, P. Repo, H. Vihinen, J. Lohi, E. Jokitalo, P. Salven, and K. Lehti, "Indications of lymphatic endothelial differentiation and endothelial progenitor cell activation in the pathology of proliferative diabetic retinopathy," *Acta Ophthalmol.*, vol. 93, no. 6, pp. 512–523, Sep. 2015, doi: 10.1111/aos.12741.
5. N. D. Roy and A. Biswas, "Early detection of proliferative diabetic retinopathy in neovascularization at the disc by observing retinal vascular structure," in *Proceedings of the International Conference on ISMAC in Computational Vision and Bio-Engineering (Lecture Notes in Computational Vision and Biomechanics)* vol. 30. Cham, Switzerland: Springer, 2019, pp. 1441–1450.
6. S. Aslani and H. Sarnel, "A new supervised retinal vessel segmentation method based on robust hybrid features," *Biomed. Signal Process. Control*, vol. 30, pp. 1–12, Sep. 2016, doi: 10.1016/j.bspc.2016.05.006.
7. D. Youssef and N. H. Solouma, "Accurate detection of blood vessels improves the detection of exudates in color fundus images," *Computed. Methods Programs Biomed.*, vol. 108, no. 3, pp. 1052–1061, Dec. 2012, doi: 10.1016/j.cmpb.2012.06.006.
8. D. N. H. Thanh, D. Sergey, V. B. Surya Prasath, and N. H. Hai, "Blood vessels segmentation method for retinal fundus images based on adaptive principal curvature and image derivative operators," *Int. Arch. Photogramm., Remote Sens. Spatial Inf. Sci.*, vol. W12, pp. 211–218, May 2019, doi: 10.5194/isprsarchives-XLII-2-W12-211-2019.
9. A. K. Shukla, R. K. Pandey, and R. B. Pachori, "A fractional filter based efficient algorithm for retinal blood vessel segmentation," *Biomed. Signal Process. Control*, vol. 59, May 2020, Art. no. 101883, doi: 10.1016/j.bspc.2020.101883

10. E. Imani, M. Javidi, and H.-R. Pourreza, “Improvement of retinal blood vessel detection using morphological component analysis,” *Comput Methods Programs Biomed.*, vol. 118, no. 3, pp. 263–279, Mar. 2015, doi: 10.1016/j.cmpb.20